



ORIGINAL ARTICLE

Spectrum of gluten-sensitive enteropathy in patients with dysmotility-like dyspepsia[☆]

Santos Santolaria^{a,*}, Javier Alcedo^a, Berta Cuartero^a, Irene Diez^a,
Manuel Abascal^b, M^a Dolores García-Prats^b, Miguel Marigil^b,
Jesús Vera^b, Margarita Ferrer^c, Miguel Montoro^a

^a Department of Gastroenterology and Hepatology, Hospital San Jorge, Huesca, Spain

^b Department of Pathology, Hospital San Jorge, Huesca, Spain

^c Department of Biochemistry, Hospital San Jorge, Huesca 22004, Spain

Received 6 June 2012; accepted 24 July 2012

Available online 23 October 2012

KEYWORDS

Dyspepsia;
Gluten-sensitive enteropathy;
Gluten-sensitivity;
Lymphocytic enteropathy;
Duodenal biopsies;
Gluten-free diet

Abstract

Background: Dysmotility-like dyspepsia symptoms are frequent in patients with gluten-sensitive enteropathy (GSE). Current data suggest that patients with mild enteropathy may be present with gluten-sensitive symptoms and complications.

Aim: To investigate the prevalence of GSE, including mild enteropathy, in patients with dysmotility-like dyspepsia symptoms.

Methods: We retrospectively studied 142 patients who presented dysmotility-like dyspepsia symptoms and normal upper gastrointestinal endoscopy. Endoscopic duodenal biopsies were taken and processed using hematoxylin–eosin staining and CD3 immunophenotyping. In patients with enteropathy (number of intraepithelial lymphocytes greater than 25 per 100 enterocytes) we also performed coeliac serology (anti-tissue transglutaminase IgA) and HLA-DQ2/DQ8 genotyping. A gluten-free diet was offered if one of these markers was positive. The final GSE diagnosis was established based on clinical and histopathological response to the gluten-free diet after 18 months of follow-up.

Results: Fifty-one patients (35.9%) had enteropathy; 4 (2.8%) Marsh type 3b, 24 (16.9%) Marsh type 3a, 3 (2.1%) Marsh type 2, and 20 (14.1%) Marsh type 1. A positive serology result was extremely low (6.7%) in mild enteropathy (Marsh type 1–3a) in contrast with Marsh type 3b patients (50%). Most patients with enteropathy had positive HLA DQ2 or -DQ8 genotyping (84.1%). Out of the 37 patients who started a gluten-free diet, 34 (91.9%) improved their symptoms, and 28 of 32 (87.5%) had a histopathological or serological response. A final GSE diagnosis was established in 28 of the 142 patients (19.7%).

[☆] Preliminary results of this study were presented as oral presentation at the 16th UEGW Vienna, 08: Santolaria S, Alcedo J, Cuartero B, Diez I, Lorente S, Abascal M, García Prats M, Marigil M, Vera J, Gimeno J, Montoro M. High prevalence of duodenal histological lesions in patients with dyspepsia and normal upper gastrointestinal endoscopy. Gut 2008;57(Suppl II):A2.

* Corresponding author.

E-mail address: ssantolariap@indogastro.org (S. Santolaria).

PALABRAS CLAVE

Dispepsia;
 Enteropatía sensible
 al gluten;
 Sensibilidad al
 gluten;
 Enteropatía
 linfocítica;
 Biopsias duodenales;
 Dieta sin gluten

Conclusion: Gluten-sensitive enteropathy can be a frequent and unsuspected cause of dysmotility-like dyspepsia.

© 2012 Elsevier España, S.L. and AEEH y AEG. All rights reserved.

Espectro de la enteropatía sensible al gluten en pacientes con dispepsia de tipo dismotilidad

Resumen

Antecedentes: La dispepsia de tipo dismotilidad es frecuente en pacientes con enteropatía sensible al gluten (ESG). Los datos actuales sugieren que los pacientes con enteropatía leve pueden presentar síntomas y complicaciones gluten dependientes.

Objetivo: Investigar la prevalencia de ESG, incluida la enteropatía leve, en pacientes con dispepsia tipo dismotilidad.

Métodos: Estudio retrospectivo de 142 pacientes que presentaban dispepsia de tipo dismotilidad y normalidad en la endoscopia digestiva alta. Se realizaron biopsias duodenales y se procesaron mediante tinción de hematoxilina-eosina e inmunofenotipo CD3. En los pacientes con enteropatía (número de linfocitos intraepiteliales superior a 25 por cada 100 enterocitos) también se realizó una serología celiaca (anti-transglutaminasa tisular IgA) y genotipado HLA-DQ2/DQ8. Si uno de estos marcadores resultaba positivo, se ofrecía al paciente iniciar una dieta sin gluten. El diagnóstico final de ESG se estableció en función de la respuesta clínica e histopatológica a la dieta sin gluten después de 18 meses de seguimiento.

Resultados: Cincuenta y un pacientes (35,9%) presentaban enteropatía, 4 (2,8%) de Marsh tipo 3b, 24 (16,9%) Marsh tipo 3a, 3 (2,1%) Marsh tipo 2, y 20 (14,1%) Marsh tipo 1. La positividad serológica fue extremadamente baja (6,7%) en la enteropatía leve (Marsh tipo 1-3a), al contrario que en los pacientes con una lesión Marsh tipo 3b (50%). La mayoría de los pacientes con enteropatía presentaban valores positivos para el genotipado HLA DQ2 o -DQ8 (84,1%). De los 37 pacientes que iniciaron una dieta sin gluten, en 34 (91,9%) mejoraron los síntomas, y 28 de 32 (87,5%) presentaron respuesta histopatológica o serológica. Un diagnóstico final de ESG se estableció en 28 de los 142 pacientes (19,7%).

Conclusión: La enteropatía sensible al gluten puede ser una causa frecuente e insospechada de dispepsia de tipo dismotilidad.

© 2012 Elsevier España, S.L. y AEEH y AEG. Todos los derechos reservados.

Introduction

Coeliac disease (CD) is an immune-mediated systemic disorder elicited by gluten and related prolamines in genetically susceptible individuals and characterised by the presence of a variable combination of gluten-dependent clinical manifestations, CD-specific antibodies, HLA-DQ2 or HLA-DQ8 haplotypes, and enteropathy.^{1,2} Current data suggest that patients with mild enteropathy (not villous atrophy) may present with gluten sensitive symptoms and complications, and that they may show good clinical and histological response to a gluten-free diet (GFD).³⁻⁸ The broader term gluten-sensitive enteropathy (GSE) comprises the whole spectrum of gluten-dependent mucosal histopathological lesions, which range from normal villous architecture with intraepithelial lymphocytosis as the only abnormality to total villous atrophy.⁹ Patients with minimal immunopathological changes in the intestine and gluten-sensitive symptoms have been diagnosed recently as suffering from non-coeliac gluten-sensitivity.¹⁰

Dyspepsia is a common symptom of GSE and may be present in up to 60% of these patients, including those with mild enteropathy.^{11,12} The prevalence of CD, based on the presence of intestinal villous atrophy, in patients with

dyspepsia is significantly higher than that in the general population, occurring at a rate of 1.2–5.8%.¹³⁻²⁰ This may be because patients with CD frequently experience gastrointestinal motility disturbances.²¹⁻²³ These motility disorders of the upper gastrointestinal tract may contribute to the development of symptoms such as postprandial fullness, bloating, flatulence, distension, nausea and/or vomiting, as well as regurgitation and heartburn.^{19,24} To the best of our knowledge, there have been no published reports on the prevalence of the whole spectrum of GSE in patients with dyspepsia.

Therefore, the aim of the present study was to investigate the prevalence of GSE, including mild enteropathy, in patients with dysmotility-like dyspepsia symptoms (DLDS) and normal upper gastrointestinal (GI) endoscopy results.

Materials and methods

Patients

This observational retrospective study examined a cohort of 142 patients seen at the endoscopy unit of San Jorge Hospital, Huesca, between January 2007 and December 2007

who was presented with DLDS but with no upper GI endoscopic evidence of structural disease that could explain their symptoms. Dysmotility-like dyspepsia definition was consistent with the Rome II criteria including a number of different nonpainful symptoms such as upper abdominal fullness, bloating, nausea, epigastric burning, belching, and vomiting.²⁵ We excluded patients with a previous diagnosis of coeliac disease, gastrectomy and/or severe systemic diseases (e.g., severe cardio-respiratory conditions, kidney or liver failure or neoplasia). Clinical data were obtained using a questionnaire, with special attention being given to symptoms, family history, and conditions associated with GSE.

The study was performed in accordance with the Declaration of Helsinki, and all patients gave their informed consent for upper GI endoscopy and for histological sampling.

Histopathological studies

During endoscopy, four endoscopic biopsies from the second and third portion of the duodenum were performed to all subjects. Additionally, gastric biopsies to rule out the presence of *Helicobacter pylori* by means of urease test were also taken. The duodenum specimens were processed using hematoxylin–eosin and immunohistochemical stains. Immunostaining for intraepithelial lymphocytes (IELs) was performed using monoclonal antibodies against CD3 (DakoCytomation, Glostrup, Denmark) in formalin-fixed, paraffin-embedded sections. The number of IELs was estimated by counting the number of CD3+ cells per 100 epithelial cells.²⁶

Histopathological findings were categorized according to the modified Marsh-Oberhuber criteria⁹; “infiltrative” lesions with intraepithelial lymphocytosis were defined as Marsh type 1 lesions, “infiltrative/hyperplastic” lesions were defined as Marsh type 2 lesions, and villous atrophy was defined as Marsh type 3 lesions (3a: partial atrophy, 3b: subtotal atrophy, 3c: total atrophy). We assumed a Marsh type 1 lesion or the presence of a lymphocytic enteropathy if the number of IELs was equal to or greater than the proportion of 25/100 epithelial cells.^{9,27} Patients with lymphocytic enteropathy (Marsh type 1), crypt hyperplasia (Marsh type 2) or partial atrophy (Marsh type 3a) were classified as having mild enteropathy.²⁸

H. pylori studies, serology and HLA

In patients with enteropathy, we also performed *H. pylori* diagnosis, antibody detection and HLA genotyping. The presence of *H. pylori* was established by a rapid urease test (CLO-test[®], Kimberly-Clark, Roswell, USA) at the time of GI endoscopy or by a ¹³C-urea breath test (UBTest[®], Otsuka Pharmaceutical Europe Ltd., Middlesex, UK) within two months of the endoscopy. The patient was considered positive for *H. pylori* infection if one of these tests were determined to be positive. Serum IgA-tissue transglutaminase antibodies (t-TGA) were analyzed using a quantitative and automated fluorescence-immunoassay method by means of a commercial available detection kit (EliA[™] Celikey[™] IgA, Phadia AB, Uppsala, Sweden). These

antibodies were considered to be positive if the values exceeded 3 U/mL. HLA-DQ2 (DQA1*05 and DQB1*02 alleles) and DQ8 (DQA1*03 and DQB1*0302 alleles) genotyping was performed via PCR amplification. A subject was considered to be genetically at-risk of developing CD when one or both alleles of the HLA-DQ2 heterodimer were positive, and when both alleles of HLA-DQ8 heterodimer were positive.²

Gluten-sensitive enteropathy diagnosis and follow-up

A gluten-free diet (GFD) was offered to enteropathy patients who either presented serology markers or were identified as immunogenetic-HLA DQ2- or DQ8-positive. Follow-up with clinical assessment was performed at 3, 6 and 18 months. Finally, a second upper GI endoscopy with duodenal biopsies was performed at 18 months.

A final diagnosis of GSE was considered when the following criteria were fulfilled²⁹: (1) a Marsh types 1–3 lesion was observed in the duodenum biopsies, (2) the presence of either serum coeliac disease or HLA-DQ2 or -DQ8 genotyping, and (3) a demonstration of gluten dependence based on significant and sustained improvement of symptoms and a histopathological or serological response to the GFD. We considered a histopathological response to have occurred when duodenal lesions decreased from Marsh type 3 to Marsh type 1 or Marsh type 0 or, in the case of Marsh type 1 lesions, when the number of IELs was normalized or reduced by 50% compared to the first histopathological study.⁸

Statistical analysis

Statistical analysis was performed using SPSS 14.0 software. Qualitative parameters were expressed as proportions, whereas quantitative variables were expressed as the mean \pm SD. The χ^2 -test and Fisher's exact test were used when appropriate for comparison between qualitative variables, while the *t*-test was used for comparison between quantitative variables. A value of *P* < 0.05 was considered to be significant.

Results

From January to December 2007, we performed a total of 1565 upper GI endoscopies, 501 (32%) of which were performed for dyspepsia evaluation. Of the 335 patients with dyspepsia and normal upper GI endoscopy, 142 with DLDS were included for this study (mean age 45.8 \pm 15 years; 73.9% females). Fifty-one of these 142 patients (35.9%) had enteropathy, including 4 (2.8%) with subtotal villous atrophy (Marsh type 3b), 24 (16.9%) with partial villous atrophy (Marsh type 3a), 3 (2.1%) with hyperplastic crypts (Marsh type 2), and 20 (14.1%) with lymphocytic enteropathy (Marsh type 1). None of the patients presented total villous atrophy (Fig. 1).

When we compared patients with and without enteropathy, we observed that patients with duodenal histopathological lesions were younger (42.4 vs. 47.7 years, *P* < 0.05),

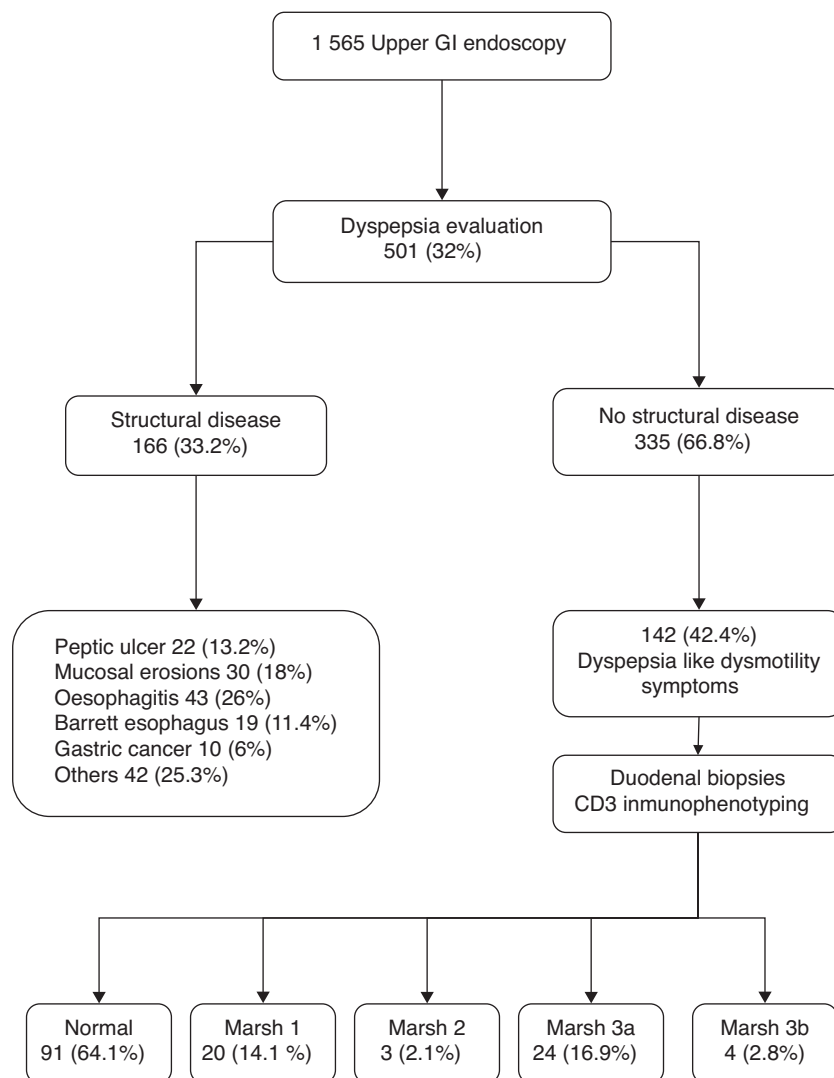


Figure 1 Selection of dyspepsia patients at the endoscopy unit.

and those patients more frequently had hypertransaminasemia (13.7% vs. 3.3%, $P < 0.05$), and a previous diagnosis of gastro-oesophageal reflux disease (27.5% vs. 13.2%, $P < 0.05$) (Table 1). Regarding the symptoms, only diarrhoea was significantly more common in patients with duodenal histopathological lesions vs. those without (31.4% vs. 14.3%, $P < 0.05$), and only abdominal distension was more frequent in patients with Marsh type 3 lesions than that in patients with Marsh type 1 or type 2 lesions (75% vs. 43.5%, $P < 0.05$) (Table 2).

Serology, HLA and *H. pylori*

Table 3 lists the frequency of serology, HLA genotyping and *H. pylori* infection by degree of intestinal lesion. Tissue transglutaminase antibodies were positive in only 3 of 39 (7.7%) patients, including 1 of 15 (6.7%) of those with Marsh type 1 lesions and 2 of 4 (50%) of those with Marsh type 3b lesions. No positive results were recorded for t-TGA in patients with Marsh type 2- or Marsh type 3a lesions.

However, most patients with enteropathy had positive HLA DQ2 or DQ8 genotyping (84.1%).

H. pylori infection was present in 15 of 44 (34.1%) patients with enteropathy and 19 of 40 (47.5%) without enteropathy ($P = 0.4$). A non-statistically significant trend of increased frequency was observed in patients with Marsh types 1–2 lesions (47.4%) compared to patients with Marsh type 3 lesions (24%, $P = 0.1$). Six patients with enteropathy and one patient without enteropathy had a history of successful *H. pylori* treatment prior to upper GI endoscopy and duodenal biopsies. Three patients with Marsh type 1 lesion (two with immunogenetic-HLA DQ2- and DQ8-negative and one without clinical response to the GFD) underwent *H. pylori* eradication treatment, but their dyspeptic symptoms did not improve.

Gluten-free diet

Fig. 2 presents the clinical evolution and final diagnoses of the 51 patients with enteropathy. Thirty-four of 37 (91.9%) patients who started a gluten-free diet improved their

Table 1 Associated clinical conditions relating to the presence or absence of enteropathy.

	Overall 142 (%)	No enteropathy 91 (%)	Enteropathy 51 (%)	<i>P</i>
Age (SD)	45.8 (15)	47.7 (15.3)	42.4 (14.1)	<0.05
Female	105 (73.9)	65 (71.4)	40 (78.4)	0.4
Smoker	35 (24.6)	21 (23.1)	14 (27.5)	0.7
Alcohol	7 (4.9)	6 (6.6)	1 (2)	0.4
NSAID	16 (11.3)	9 (9.9)	7 (13)	0.6
Family history of GSE	9 (6.3)	3 (3.3)	6 (11.8)	0.07
Diabetes	6 (4.2)	4 (4.4)	2 (3.9)	1
Anxiety or depression	33 (23.2)	26 (28.6)	7 (13.7)	0.07
Miscarriages	6 (4.2)	4 (4.4)	2 (3.9)	1
Mouth sores	14 (9.9)	7 (7.7)	7 (13.7)	0.2
GORD	26 (18.3)	12 (13.2)	14 (27.5)	0.04
Functional dyspepsia	25 (17.6)	14 (15.4)	11 (21.6)	0.4
IBS	18 (12.7)	12 (13.2)	6 (11.8)	1
Ferropenic anaemia	33 (23.2)	21 (23.1)	12 (23.5)	1
Articular symptoms	18 (12.7)	15 (16.5)	3 (5.9)	0.1
Osteoporosis	13 (9.2)	7 (7.7)	6 (11.8)	0.3
Dermatitis	6 (4.2)	3 (3.3)	3 (5.9)	0.7
Hypertransaminasemia	10 (7)	3 (3.3)	7 (13.7)	0.03
Autoimmune disorders	11 (7.7)	7 (7.7)	4 (7.8)	1
Bronchial asthma	7 (4.9)	5 (5.5)	2 (3.9)	1

NSAID: non steroidal antiinflammatory drugs; GSE: gluten-sensitive enteropathy; GORD: gastro-oesophageal reflux disease; IBS: irritable bowel syndrome.

Table 2 Symptoms associated with postprandial fullness in relation to the presence or absence of enteropathy.

	No enteropathy 91 (%)	Enteropathy		
		Overall 51 (%)	Marsh 1–2 23 (%)	Marsh 3 28 (%)
Bloating	53 (58.2)	35 (68.6)	15 (65.2)	20 (71.4)
Abdominal distension	57 (62.6)	31 (60.8)	10 (43.5)	21 (75) ^b
Nausea/vomiting	30 (33)	13 (25.5)	3 (13)	10 (35.7)
Heartburn (>3/week)	27 (29.7)	23 (45.1)	10 (43.5)	13 (46.4)
Regurgitation	20 (22)	15 (29.4)	4 (17.4)	11 (39.3)
Diarrhoea	13 (14.3)	16 (31.4) ^a	7 (30.4)	9 (32.1)
Constipation	24 (26.4)	15 (29.4)	8 (34.8)	7 (25)
Diarrhoea/constipation	18 (17.8)	9 (17.6)	3 (13)	6 (21.4)
Weight loss	19 (20.9)	4 (7.8)	2 (8.7)	2 (7.1)
Asthenia	11 (12.1)	8 (15.7)	3 (13)	5 (17.9)
Abdominal pain	18 (19.8)	8 (15.7)	5 (21.7)	3 (10.7)

^a *P* < 0.05 when compared with patients without enteropathy.

^b *P* < 0.05 when compared with patients with Marsh 1–2 lesions.

Table 3 Serology, HLA immunogenetic and *H. pylori* diagnosis in patients with enteropathy.

	t-TGAn (%)	HLA-DQ2n (%)	Homozygous	Heterozygous	HLA-DQ8n (%)	HLA-DQ2 or -DQ8n (%)	<i>H. pylori</i> n (%)
Marsh 1	1/15 (6.7)	13/17 (76.5)	10/17	3/17	4/17 (23.5)	14/17 (82.4)	8/16 (50)
Marsh 2	0/2	2/2 (100)	2/2	0/2	0/1	2/2 (100)	1/3 (33.3)
Marsh 3a	0/18	16/22 (72.7)	6/22	10/22	5/22 (22.7)	18/22 (81.8)	5/21 (23.8)
Marsh 3b	2/4 (50)	3/3 (100)	3/3	0/3	0/3	3/3 (100)	1/4 (25)
Overall	3/39 (7.7)	34/44 (77.3)	21/44	13/44	9/43 (20.9)	37/44 (84.1)	15/44 (34.1)

t-TGA: IgA-tissue transglutaminase antibodies; HLA-DQ2: presence of immunogenetic HLA-DQ2 (either one or both alleles); HLA-DQ8: presence of immunogenetic HLA-DQ8 (both alleles).

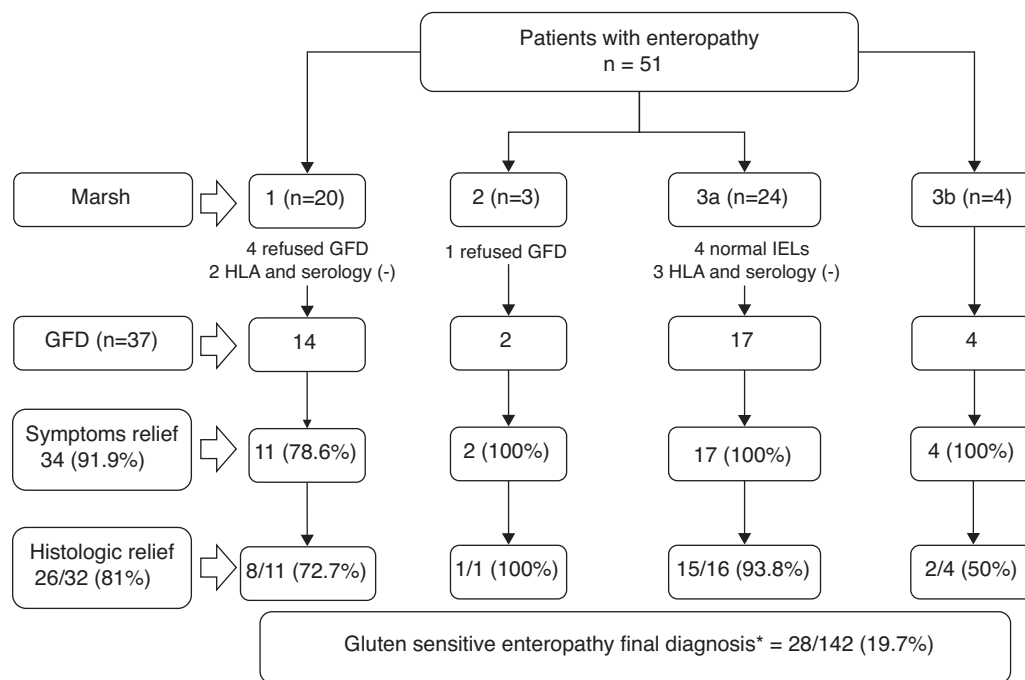


Figure 2 Clinical evolution and final diagnosis of the 51 patients with enteropathy (GFD: gluten-free diet; IELs: duodenal intraepithelial lymphocytes).

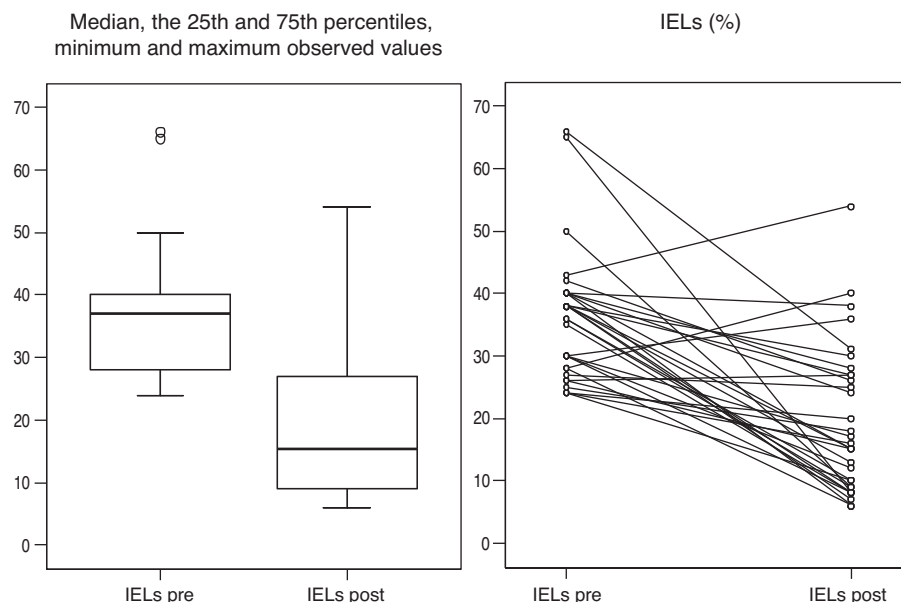


Figure 3 Duodenal intraepithelial lymphocytes (IELs) before and after implementation of a gluten-free diet (GFD).

dyspeptic symptoms (78.6% Marsh type 1, 100% Marsh type 2, 100% Marsh type 3a, 100% Marsh type 3b), and 26 of 32 (81%) patients who accepted and received a second upper GI endoscopy presented an improvement of histopathological lesions (72.7% Marsh type 1, 100% Marsh type 2, 93.8% Marsh type 3a, 50% Marsh type 3b). In these patients, duodenal intraepithelial lymphocytes counts also improved following the GFD. The IELs counts and means

decreased from 36 ± 10.2 to 19.2 ± 11.9 ($P < 0.001$, Fig. 3). Two patients presenting with Marsh type 3b lesions, the presence of t-TGA and without histopathological improvement, were also diagnosed with GSE based on their clinical and serological responses (i.e., normalization of t-TGA) to the GFD. A final GSE diagnosis was thus established in 28 of 142 patients (19.7%). Table 4 shows serology, HLA-DQ type, histopathology and *H. pylori* diagnosis in these patients.

Table 4 Serology, HLA-DQ type, histopathology and *H. pylori* diagnosis in gluten-sensitive enteropathy patients.

ID	Age	Sex	Marsh	t-TGA	HLA-DQ type	IELs	IELs post GFD	Marsh post GFD	Histologic relief	<i>H. pylori</i>
1	24	Male	1	Neg	DQ2 heterozygous/DQ8	28	6	0	Yes	Neg
2	47	Female	1	Neg	DQ2 heterozygous/DQ8	65	8	0	Yes	Neg
3	24	Female	1	Neg	DQ2 homozygous	40	28	1	Yes	Pos
4	37	Female	1	Neg	DQ2 homozygous	66	31	1	Yes	Pos
5	63	Female	1	Neg	DQ2 homozygous	26	15	0	Yes	Pos
6	22	Female	1	Neg	DQ2 homozygous	40	24	1	Yes	Pos
7	62	Female	1	Neg	DQ2 homozygous/DQ8	36	10	0	Yes	Pos
8	31	Female	1	Neg	DQ2 homozygous	50	9	0	Yes	Pos
9	50	Female	2	Neg	DQ2 homozygous	25	18	0	Yes	Pos
10	23	Female	3a	–	DQ2 homozygous	38	13	0	Yes	Pos
11	50	Female	3a	Neg	DQ2 heterozygous	25	20	0	Yes	Neg
12	56	Female	3a	Neg	DQ2 heterozygous	25	16	0	Yes	–
13	20	Male	3a	Neg	DQ2 heterozygous	30	8	0	Yes	Neg
14	44	Male	3a	Neg	DQ2 heterozygous	40	15	0	Yes	Neg
15	49	Female	3a	Neg	DQ8	30	12	0	Yes	Pos
16	29	Female	3a	Neg	DQ8	25	10	0	Yes	Pos
17	54	Female	3a	Neg	DQ2 heterozygous	40	6	0	Yes	Neg
18	29	Male	3a	Neg	DQ2 heterozygous/DQ8	35	8	0	Yes	Pos
19	50	Male	3a	Neg	DQ2 homozygous	38	15	0	Yes	Neg
20	49	Male	3a	–	DQ2 homozygous	36	9	0	Yes	Neg
21	62	Female	3a	Neg	DQ2 homozygous/DQ8	38	8	0	Yes	Neg
22	34	Female	3a	Neg	DQ2 homozygous/DQ8	30	17	0	Yes	–
23	55	Female	3a	Neg	DQ2 homozygous	26	27	1	Yes	Pos
24	49	Female	3a	Neg	DQ2 homozygous	42	26	1	Yes	Neg
25	25	Female	3b	Neg	–	38	7	0	Yes	Neg
26	64	Female	3b	Neg	DQ2 heterozygous	38	27	1	Yes	Neg
27	35	Female	3b	Pos	DQ2 heterozygous	40	38	3b	No ^a	Pos
28	24	Female	3b	Pos	DQ2 heterozygous	43	54	3b	No ^a	Neg

t-TGA: IgA-tissue transglutaminase antibodies; IELs: duodenal intraepithelial lymphocytes; GFD: gluten-free diet.

^a These patients presented clinical improvement and normalization of t-TGA after GFD.

Discussion

Gluten-sensitive enteropathy has a wide and heterogeneous spectrum of clinical manifestations, ranging from symptomless manifestations to the classical gastrointestinal form with diarrhoea and weight loss with a great variety of atypical clinical manifestations in between, such as anaemia, osteopenia, dermatitis, abdominal pain, amongst others.³⁰ Dyspepsia is also a common symptom that may be present in up to 60% of GSE patients.^{11,12,24} Moreover, the prevalence of CD, based on the presence of intestinal villous atrophy, in patients with dyspepsia is significantly higher than that in the general population, occurring at a rate that varies from 1.2 to 5.8%.^{13–20}

In the present study, we found a higher prevalence of GSE (19.7%) than that found in previous studies. This unexpected prevalence can be explained by several reasons. Firstly, we included a select subgroup of patients with dyspepsia (namely, those with dysmotility symptoms). All these patients were referred to the endoscopy unit for etiologic diagnosis of dyspepsia, allowing us to include patients in real clinical practice. Secondly, in contrast to previous studies the presence of intestinal villous atrophy and serologic markers were not considered to be necessary criteria for the final diagnosis of GSE. In addition, our pathologists

processed the duodenal specimens using CD3 lymphocytic immunophenotyping, a useful diagnostic tool for increasing the likelihood of detecting of lymphocytic enteropathy, especially when atrophy is absent.²⁶

Why have we chosen to include only patients with dyspepsia-like dysmotility symptoms in this study? Patients with GSE frequently have gastrointestinal motor disturbances. There are studies that have shown a delay in oesophageal transit, gastric and gallbladder emptying, in addition to orocecal transit time compared to colonic transit.²¹ These motility disorders of the upper gastrointestinal tract could contribute to the development of symptoms such as postprandial fullness, bloating, flatulence, distension, nausea and/or vomiting, as well as regurgitation and heartburn.^{19,24} Based on these reports, we thought that those patients with dyspepsia and dysmotility symptoms may be a risk group for GSE. Motility disorders in patients with GSE have been related to complex interactions among the reduced absorption of certain food constituents (for example, fat or starch), a dysfunction in the autonomic nervous system, and derangements of the secretion of several hormones such as cholecystokinin, neurotensin, plasma peptide YY, ghrelin and somatostatin. Fortunately, most of these changes usually disappear after a GFD is implemented.^{22,23,31–33}

Why have we considered patients with mild enteropathy for the diagnosis of GSE in this study? Current data suggest that patients with Marsh types 1–2 lesions and testing positive for endomysial antibodies may suffer from GI symptoms and complications, such as abnormal bone mineral density, as frequently as patients with overt villous atrophy.^{34,35} Patients with mild enteropathy and negative coeliac serology may also have gluten-sensitive symptoms and complications, such as abdominal pain, distension, diarrhoea, anaemia, osteopenia or hypertransaminasemia.⁴ Furthermore, several prospective, although not controlled, studies have suggested that most of these patients may show good clinical and histological responses to a GFD.^{5–8}

However, there are conditions other than GSE in which a duodenal intraepithelial lymphocytosis is possible.^{36,37} Examples of these include *H. pylori* infection, non-steroidal anti-inflammatory drugs, peptic duodenitis, small intestinal bacterial overgrowth, food protein intolerance (e.g., cow's milk, peanuts and eggs), tropical sprue, autoimmune disorders, eosinophilic gastroenteritis, Crohn's disease, lymphocytic colitis and common variable immunodeficiency.⁹ In the present study, most patients had mild histological lesions and negative coeliac serology, and not all these were finally diagnosed with GSE (Fig. 2). According to the recommendation of Collin et al.,²⁹ we have taken into account further evidence in order to diagnose GSE in these patients with borderline enteropathy. Firstly, we performed tests for immunogenetic markers (HLA DQ2 or DQ8) and for specific antibodies (t-TGA). HLA-DQ2 and DQ8 genotyping has a very high negative predictive value for coeliac disease.^{38,39} If one of these genetic or serologic markers was positive, we offered the patient the opportunity to start a GFD. Secondly, we proved gluten dependence based on the improvement of symptoms and histologic inflammation at an 18-month follow-up. A final GSE diagnosis was established in those patients who improved their symptoms and histopathological or serology abnormalities after undertaking the GFD. The subset characterization of $\gamma\delta$ + IELs and the immunohistologic detection of IgA anti-transglutaminase subepithelial deposits may offer additional value for the diagnosis of GSE but these techniques are not straightforward for use in clinical practice.^{40,41}

Despite the indication in previous studies of the excellent sensitivity and specificity of serology for GSE diagnosis, we found a surprisingly low positivity when testing for t-TGA (7.7%). This may be explained by the fact that the prevalence of t-TGA may be correlated with the degree of intestinal damage; indeed, it has been reported that these antibodies often remain negative in partial villous atrophy or in the absence of atrophy.^{42,43} In our study, the great majority of patients had only mild enteropathy. In these patients, positive serum antibodies were extremely low (6.7%) in contrast with patients with subtotal villous atrophy (50%). Consequently, the negativity of the serologic test in the cases of mild enteropathy does not rule out GSE, and these tests performed without histologic evaluation may underestimate the real prevalence of GSE. For this reason, duodenal biopsies are still recommended in patients with strong clinical suspicion of GSE, even if serologic testing is negative.^{1,44}

In view of these results, a change could be suggested in the diagnosis workup for patients with dyspepsia. According to the Roma III criteria, functional dyspepsia is defined as the presence of epigastric pain or burning, postprandial fullness or early satiation in the absence of an underlying organic disease likely to explain the symptoms.²⁵ Upper GI endoscopy is the gold standard for excluding an organic cause of dyspepsia. However, the absence of a structural disease at an upper GI endoscopy is not enough to exclude an organic cause of dyspepsia, such as GSE, the diagnosis of which is based on the presence of histopathological small intestinal mucosal damage. Consequently, duodenal biopsies might improve the etiologic diagnoses in patients presenting dysmotility-like dyspepsia (or postprandial distress syndrome according to Roma III criteria) when an upper GI endoscopy does not provide evidence of a structural disease explaining the symptoms. However, the present study has several shortcomings that may have limited the possible clinical application of these results. Firstly, we did not take biopsies from all dyspepsia patients who underwent endoscopy; thus, we did not have a control group. Secondly, the data from the patients who received a GFD were uncontrolled. Consequently, we cannot definitively rule out a placebo effect for the positive response. Although we provided compelling evidence of clinical and histopathological responses to the GFD, we did not give a subsequent gluten challenge to the patients. Therefore, it will be necessary to confirm these preliminary results in randomized, therapeutic trials to determine whether dyspepsia patients with mild enteropathy and without positive coeliac serology will benefit from a GFD.

In conclusion, the present study shows that GSE can be a frequent and unsuspected cause of postprandial distress or dysmotility-like dyspepsia. If these results are confirmed in randomized, controlled clinical studies, duodenal biopsies with CD3 immunophenotyping should be considered as part of the approach for determining a diagnosis of dyspepsia if there is no evidence for a structural disease that could explain the symptoms at the time of an upper GI endoscopy.

Funding

Writing support was provided by American Journal Experts and funded by INDOGASTRO foundation.

Conflicts of interest

The authors have no conflicts of interest to declare.

Acknowledgements

We would like to thank Dr. Maria Esteve and Dr. Fernando Fernandez Bañares from the Department of Gastroenterology at the Hospital Universitari Mútua Terrassa for their valuable suggestions and critical review of the manuscript. We also gratefully thank to Shirley Hooper for the English review in the revised manuscript.

References

- Husby S, Koletzko S, Korponay-Szabo IR, Mearin ML, Phillips A, Shamir R, et al. European Society for Pediatric Gastroenterology, Hepatology, and Nutrition guidelines for the diagnosis of coeliac disease. *J Pediatr Gastroenterol Nutr.* 2012;54:136–60.
- Kagnoff MF. AGA Institute Medical Position statement on the diagnosis and management of celiac disease. *Gastroenterology.* 2006;131:1977–80.
- Kurppa K, Collin P, Viljamaa M, Haimila K, Saavalainen P, Partanen J, et al. Diagnosing mild enteropathy celiac disease: a randomized, controlled clinical study. *Gastroenterology.* 2009;136:816–23.
- Esteve M, Rosinach M, Fernandez-Banares F, Farre C, Salas A, Alsina M, et al. Spectrum of gluten-sensitive enteropathy in first-degree relatives of patients with coeliac disease: clinical relevance of lymphocytic enteritis. *Gut.* 2006;55:1739–45.
- Wahab PJ, Crusius JB, Meijer JW, Mulder CJ. Gluten challenge in borderline gluten-sensitive enteropathy. *Am J Gastroenterol.* 2001;96:1464–9.
- Tursi A, Brandimarte G. The symptomatic and histologic response to a gluten-free diet in patients with borderline enteropathy. *J Clin Gastroenterol.* 2003;36:13–7.
- Fernandez-Bañares F, Esteve M, Salas A, Alsina M, Farre C, Gonzalez C, et al. Systematic evaluation of the causes of chronic watery diarrhoea with functional characteristics. *Am J Gastroenterol.* 2007;102:2520–8.
- Monzon H, Forne M, Gonzalez C, Esteve M, Marti JM, Rosinach M, et al. Mild enteropathy as a cause of iron-deficiency anaemia of previously unknown origin. *Dig Liver Dis.* 2011;43:448–53.
- Ensari A. Gluten-sensitive enteropathy (celiac disease): controversies in diagnosis and classification. *Arch Pathol Lab Med.* 2010;134:826–36.
- Verdu EF, Armstrong D, Murray JA. Between coeliac disease and irritable bowel syndrome: the “No Man’s Land” of gluten sensitivity. *Am J Gastroenterol.* 2009;104:1587–94.
- Ciacchi C, Cirillo M, Sollazzo R, Savino G, Sabbatini F, Mazzacca G. Gender and clinical presentation in adult coeliac disease. *Scand J Gastroenterol.* 1995;30:1077–81.
- Zipser RD, Patel S, Yahya KZ, Baisch DW, Monarch E. Presentations of adult celiac disease in a nationwide patient support group. *Dig Dis Sci.* 2003;48:761–4.
- Dickey W, Hughes D. Prevalence of celiac disease and its endoscopic markers among patients having routine upper gastrointestinal endoscopy. *Am J Gastroenterol.* 1999;94:2182–6.
- Bardella MT, Minoli G, Ravizza D, Radaelli F, Velio P, Quatrini M, et al. Increased prevalence of celiac disease in patients with dyspepsia. *Arch Intern Med.* 2000;160:1489–91.
- Vivas S, Ruiz de Morales JM, Martinez J, González MC, Martín S, Martín J, et al. Human recombinant anti-transglutaminase antibody testing is useful in the diagnosis of silent coeliac disease in a selected group of at-risk patients. *Eur J Gastroenterol Hepatol.* 2003;15:479–83.
- Locke 3rd GR, Murray JA, Zinsmeister AR, Melton 3rd LJ, Talley NJ. Celiac disease serology in irritable bowel syndrome and dyspepsia: a population-based case-control study. *Mayo Clin Proc.* 2004;79:476–82.
- Lima VM, Gandolfi L, Pires JA, Pratesi R. Prevalence of celiac disease in dyspeptic patients. *Arq Gastroenterol.* 2005;42:153–6.
- Ozaslan E, Akkorlu S, Eskioğlu E, Kayhan B. Prevalence of silent celiac disease in patients with dyspepsia. *Dig Dis Sci.* 2007;52:692–7.
- Giangreco E, D’Agate C, Barbera C, Puzzo L, Aprile G, Naso P, et al. Prevalence of celiac disease in adult patients with refractory functional dyspepsia: value of routine duodenal biopsy. *World J Gastroenterol.* 2008;14:6948–53.
- Ford AC, Ching E, Moayyedi P. Meta-analysis: yield of diagnostic tests for coeliac disease in dyspepsia. *Aliment Pharmacol Ther.* 2009;30:28–36.
- Tursi A. Gastrointestinal motility disturbances in celiac disease. *J Clin Gastroenterol.* 2004;38:642–5.
- Bassotti G, Villanacci V, Mazzocchi A, Mariano M, Incardona P, Clerici C, et al. Antroduodenal motor activity in untreated and treated celiac disease patients. *J Gastroenterol Hepatol.* 2008;23:E23–8.
- Rocco A, Sarnelli G, Compare D, De Colibus P, Micheli P, Somma P, et al. Tissue ghrelin level and gastric emptying rate in adult patients with celiac disease. *Neurogastroenterol Motil.* 2008;20:884–90.
- Giorgetti GM, Tursi A, Brandimarte G, Rubino E, Gasbarrini G. Dysmotility-like dyspeptic symptoms in coeliac patients: role of gluten and *Helicobacter pylori* infection. *Dig Liver Dis.* 2000;32:73–4.
- Geeraerts B, Tack J. Functional dyspepsia: past, present, and future. *J Gastroenterol.* 2008;43:251–5.
- Mino M, Lauwers GY. Role of lymphocytic immunophenotyping in the diagnosis of gluten-sensitive enteropathy with preserved villous architecture. *Am J Surg Pathol.* 2003;27:1237–42.
- Veress B, Franzen L, Bodin L, Borch K. Duodenal intraepithelial lymphocyte-count revisited. *Scand J Gastroenterol.* 2004;39:138–44.
- Vivas S, Ruiz de Morales JM, Fernandez M, Hernando M, Herrero B, Casqueiro J, et al. Age-related clinical, serological, and histopathological features of celiac disease. *Am J Gastroenterol.* 2008;103:2360–5.
- Collin P, Wahab PJ, Murray JA. Intraepithelial lymphocytes and coeliac disease. *Best Pract Res Clin Gastroenterol.* 2005;19:341–50.
- Rodrigo L. Celiac disease. *World J Gastroenterol.* 2006;12:6585–93.
- Usai P, Usai Satta P, Lai M, Corda MG, Piras E, Calcara C, et al. Autonomic dysfunction and upper digestive functional disorders in untreated adult coeliac disease. *Eur J Clin Invest.* 1997;27:1009–15.
- Bardella MT, Fraquelli M, Peracchi M, Cesana BM, Bianchi PA, Conte D. Gastric emptying and plasma neurotensin levels in untreated coeliac patients. *Scand J Gastroenterol.* 2000;35:269–73.
- Lanzini A, Magni P, Petroni ML, Motta M, Lanzarotto F, Villanacci V, et al. Circulating ghrelin level is increased in coeliac disease as in functional dyspepsia and reverts to normal during gluten-free diet. *Aliment Pharmacol Ther.* 2006;23:907–13.
- Kaukinen K, Maki M, Partanen J, Sievanen H, Collin P. Celiac disease without villous atrophy: revision of criteria called for. *Dig Dis Sci.* 2001;46:879–87.
- Kurppa K, Collin P, Sievanen H, Huhtala H, Maki M, Kaukinen K. Gastrointestinal symptoms, quality of life and bone mineral density in mild enteropathic coeliac disease: a prospective clinical trial. *Scand J Gastroenterol.* 2010;45:305–14.
- Vande Voort JL, Murray JA, Lahr BD, Van Dyke CT, Kroning CM, Moore SB, et al. Lymphocytic duodenitis and the spectrum of celiac disease. *Am J Gastroenterol.* 2009;104:142–8.
- Aziz I, Evans KE, Hopper AD, Smillie DM, Sanders DS. A prospective study into the aetiology of lymphocytic duodenitis. *Aliment Pharmacol Ther.* 2010;32:1392–7.
- Kaukinen K, Partanen J, Maki M, Collin P. HLA-DQ typing in the diagnosis of celiac disease. *Am J Gastroenterol.* 2002;97:695–9.
- Kapitany A, Toth L, Tumpek J, Csipo I, Sipos E, Woolley N, et al. Diagnostic significance of HLA-DQ typing in patients with previous coeliac disease diagnosis based on histology alone. *Aliment Pharmacol Ther.* 2006;24:1395–402.

40. Jarvinen TT, Kaukinen K, Laurila K, Kyronpalo S, Rasmussen M, Maki M, et al. Intraepithelial lymphocytes in celiac disease. *Am J Gastroenterol.* 2003;98:1332-7.
41. Korponay-Szabo IR, Halttunen T, Szalai Z, Laurila K, Kiraly R, Kovacs JB, et al. In vivo targeting of intestinal and extraintestinal transglutaminase 2 by coeliac autoantibodies. *Gut.* 2004;53:641-8.
42. Rostami K, Kerckhaert J, Tiemessen R, von Blomberg BM, Meijer JW, Mulder CJ. Sensitivity of antiendomysium and antigliadin antibodies in untreated celiac disease: disappointing in clinical practice. *Am J Gastroenterol.* 1999;94:888-94.
43. Tursi A, Brandimarte G, Giorgetti GM. Prevalence of antitissue transglutaminase antibodies in different degrees of intestinal damage in celiac disease. *J Clin Gastroenterol.* 2003;36:219-21.
44. Hopper AD, Cross SS, Hurlstone DP, McAlindon ME, Lobo AJ, Hadjivassiliou M, et al. Pre-endoscopy serological testing for coeliac disease: evaluation of a clinical decision tool. *BMJ.* 2007;334:729.